



INTERVERTEBRAL DISC DISEASE (IVDD)

What is INTERVERTEBRAL DISC DISEASE?

It is the degeneration and bulging or herniation of an intervertebral disc into the spinal canal placing pressure on the spinal cord. The spinal column is made up of many bones called vertebrae. Intervertebral discs sit between the bottom halves of adjacent vertebrae providing cushion and a point of attachment between the two bones. The spinal cord travels through the central canal of the spinal column just above the level of the intervertebral discs. Normal discs can be compared to a jelly doughnut in that they have a gelatinous inner portion (nucleus pulposus) contained within a very firm outer layer (annulus fibrosus).

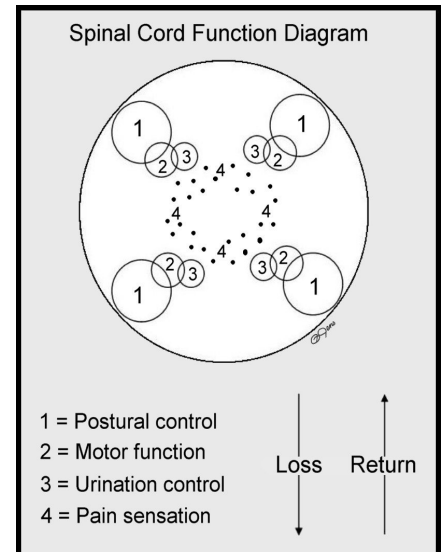
The most common type of disc disease is when the inner nucleus slowly leaks out or rapidly erupts into the spinal canal causing compression and sometimes concussion of the spinal cord. The severity of clinical signs will depend upon the degree of cord compression and/or concussion. This type of IVDD is most common in chondrodystrophic breeds, (Dachshund, Basset hound, Beagle, Cocker spaniel) but can occur in any breed. A second type of IVDD is where the outer annulus bulges into the spinal canal without rupturing. Clinical signs usually occur over a longer period of time with pain being the hallmark. However if the cord compression becomes significant, patients will display similar clinical signs as those with nuclear type herniation. This type of disc degeneration usually occurs in older, larger breeds such as German shepherd dogs and Labrador retrievers but can occur in any breed.

Diagnosis

A presumptive diagnosis of IVDD is based on historical information, neurological examination and results of a myelogram. A myelogram is when a liquid contrast agent, which can be seen on x-rays, is injected into the spinal fluid surrounding the spinal cord. After the contrast agent is injected, spinal x-rays allow visualization of compressive spinal cord lesions (such as a herniated disc or a tumor).

Treatment

If the patient has pain and/or mild neurological deficits, medical management can be affective. The patient must be strictly confined for 4 to 6 weeks and given anti-inflammatory medications to reduce swelling and decrease discomfort. If the pet is unable to walk, this indicates a significant spinal cord compression and surgical intervention is recommended. The surgical procedure (hemilaminectomy) involves cutting away part of two adjacent vertebrae allowing access to the spinal canal to remove the herniated or bulging disc material relieving the pressure placed on the spinal cord. Prognosis is directly related to the pre-surgical neurological status and duration of clinical signs. Acute cases with mild deficits have an excellent prognosis and more chronic cases with severe deficits will have a poorer prognosis.



**For more information visit Veterinary Specialty & Emergency Care
at www.vetspecialtycare.com**