



## CRUCIATE TEAR REPAIR LATERAL FABELLAR SUTURES

### What is Cranial Cruciate Ligament Function/Injury?

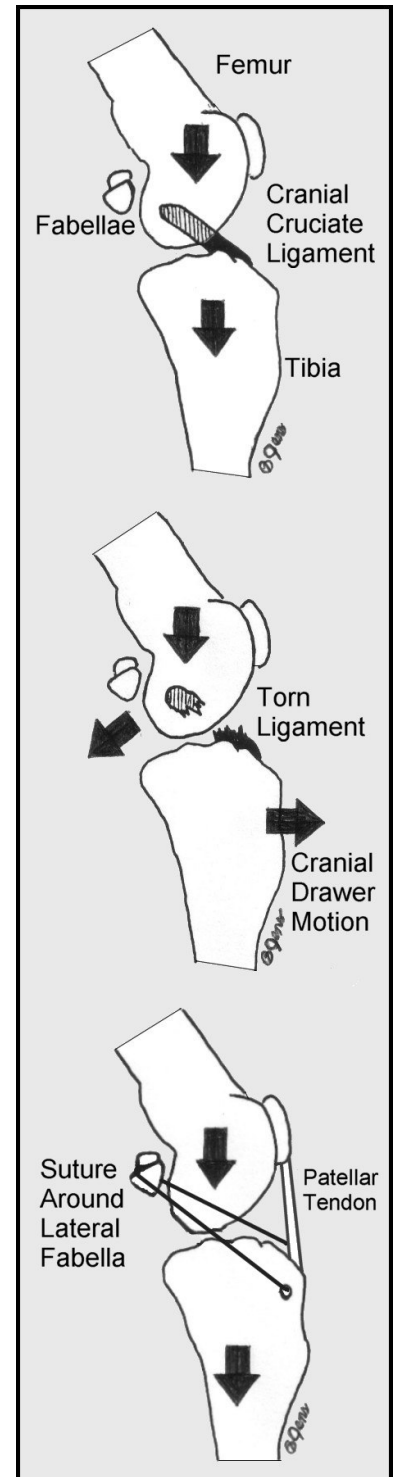
Many tendons and ligaments are involved in providing stability to the stifle (knee joint). The cranial cruciate ligament provides the same support as the anterior cruciate ligament does in humans. This ligament prevents forward motion of the tibia (shin) and backward motion of the femur (thigh bone) when weight is placed on the limb. If this ligament tears, the femur will slide down the back slope of the tibia plateau and weight will be transferred to the joint capsule and other soft tissue structures resulting in pain and inflammation. Ultimately, this ongoing inflammation will result in the development of degenerative osteoarthritis and persistent and often progressively worsening rear limb lameness.

### Diagnosis

Rupture of the cranial cruciate ligament is diagnosed by taking a thorough history, performing a comprehensive physical examination, and reviewing x-rays of the knee. Acute onset of single rear limb lameness after activity would be a classic history. Dogs will slowly begin using the limb within a few days of sustaining the injury and show discomfort with manipulation of the knee. A specific manipulation during the exam is performed to elicit stifle laxity (cranial drawer motion). This laxity or looseness between the tibia and the femur cannot exist if the cranial cruciate ligament is intact. The presence of cranial drawer is diagnostic for cranial cruciate ligament rupture. This manipulation may need to be performed under sedation or anesthesia due to patient resistance. X-rays are used to evaluate the knee for signs of arthritis and effusion (fluid in the joint) and to help exclude other predisposing or complicating conditions. Diagnosis of cruciate ligament injury is confirmed during the surgical repair procedure by direct visualization or by arthroscopic exam of the joint.

### Lateral Fabellar Suture Technique

To neutralize the stifle laxity (cranial drawer) a prosthetic ligament is surgically implanted to mimic the function of an intact cranial cruciate ligament. This technique utilizes at least two heavy gauge nylon suture loops placed around the lateral fabella and through a hole drilled in the front of the tibia. These sutures are tight when weight is placed on the limb and they prevent the abnormal cranial drawer motion within the joint. With restricted activity, physical therapy and time, the formation of scar tissue will provide long-term stabilization of the joint. If the sutures are over strained and stretched or torn before adequate scar tissue forms, the function of the knee will be poor due to the reintroduction of joint laxity.



For more information visit **Veterinary Specialty & Emergency Care**  
at [www.vetspecialtycare.com](http://www.vetspecialtycare.com)